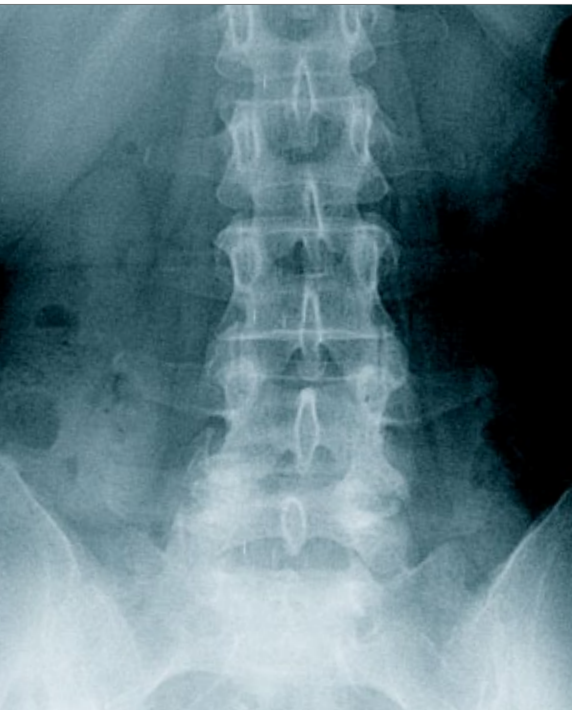
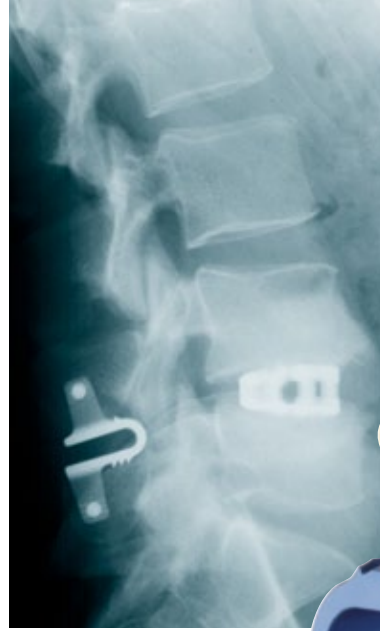
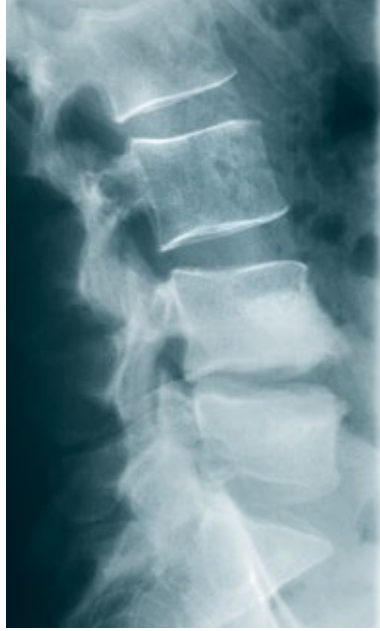
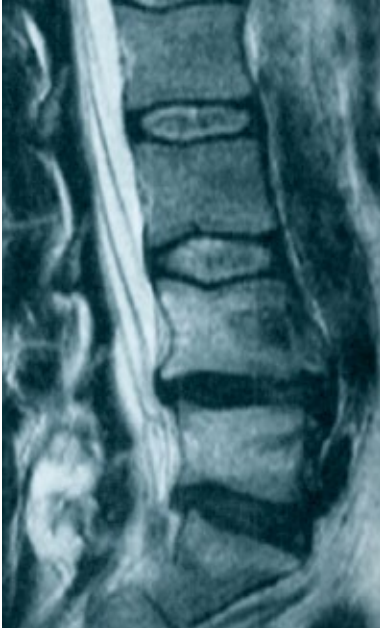
Minimally Invasive
Lumbar Fusion

coflex-F™

Interlaminar Technology



Minimally Invasive

With the introduction of pedicle screws in the 1980s and cages in the 1990s, lumbar fusion with instrumentation became a common procedure for treating degenerative disc disease. Scientific literature demonstrates that many posterior fixation techniques that utilize pedicle screws and rods, interspinous graft with ligament or translaminar screws improve the fusion rates of both stand-alone intervertebral grafting and stand-alone intervertebral implants.

The *coflex-F*TM implant is an interlaminar stabilization device that can be delivered through a minimally invasive approach. It provides significant segmental stability and

posterior fixation for anterior column fusion. Biomechanical studies demonstrate that the solid anchoring of the *coflex-F* implant through rigid connection to the spinous processes provides similar posterior stabilization as pedicle screws thereby increasing the likelihood of successful anterior fusion (Table 1).

The implantation technique is safe and easy. Complications encountered with the conventional pedicle screw systems can be avoided.

The *coflex-F* implant offers an important alternative to pedicle screw fixation as an adjunct to intervertebral fusion.

Biomechanical Rationale

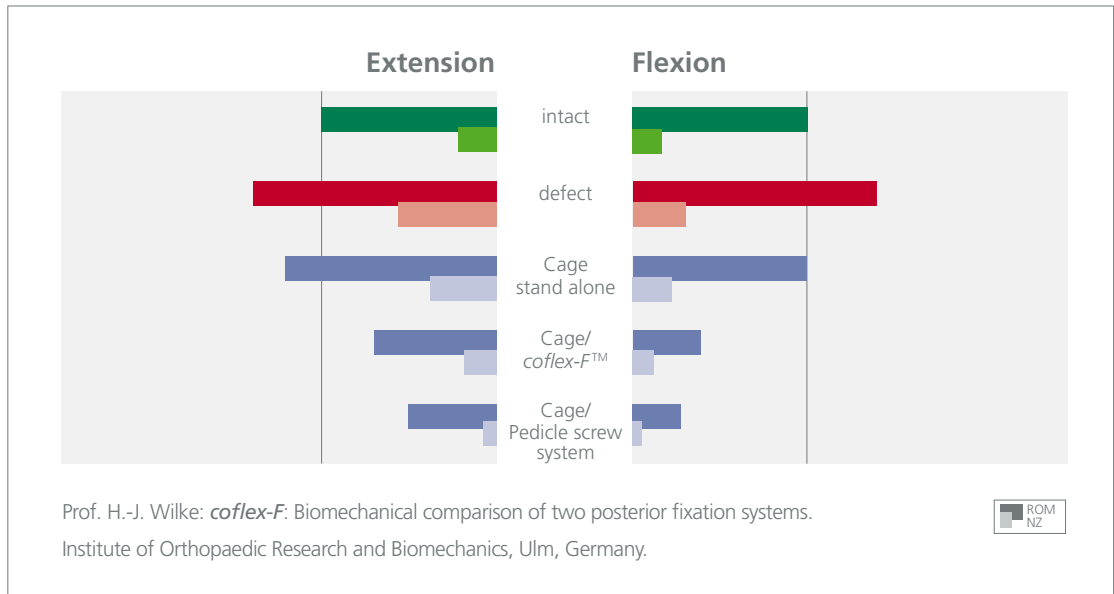
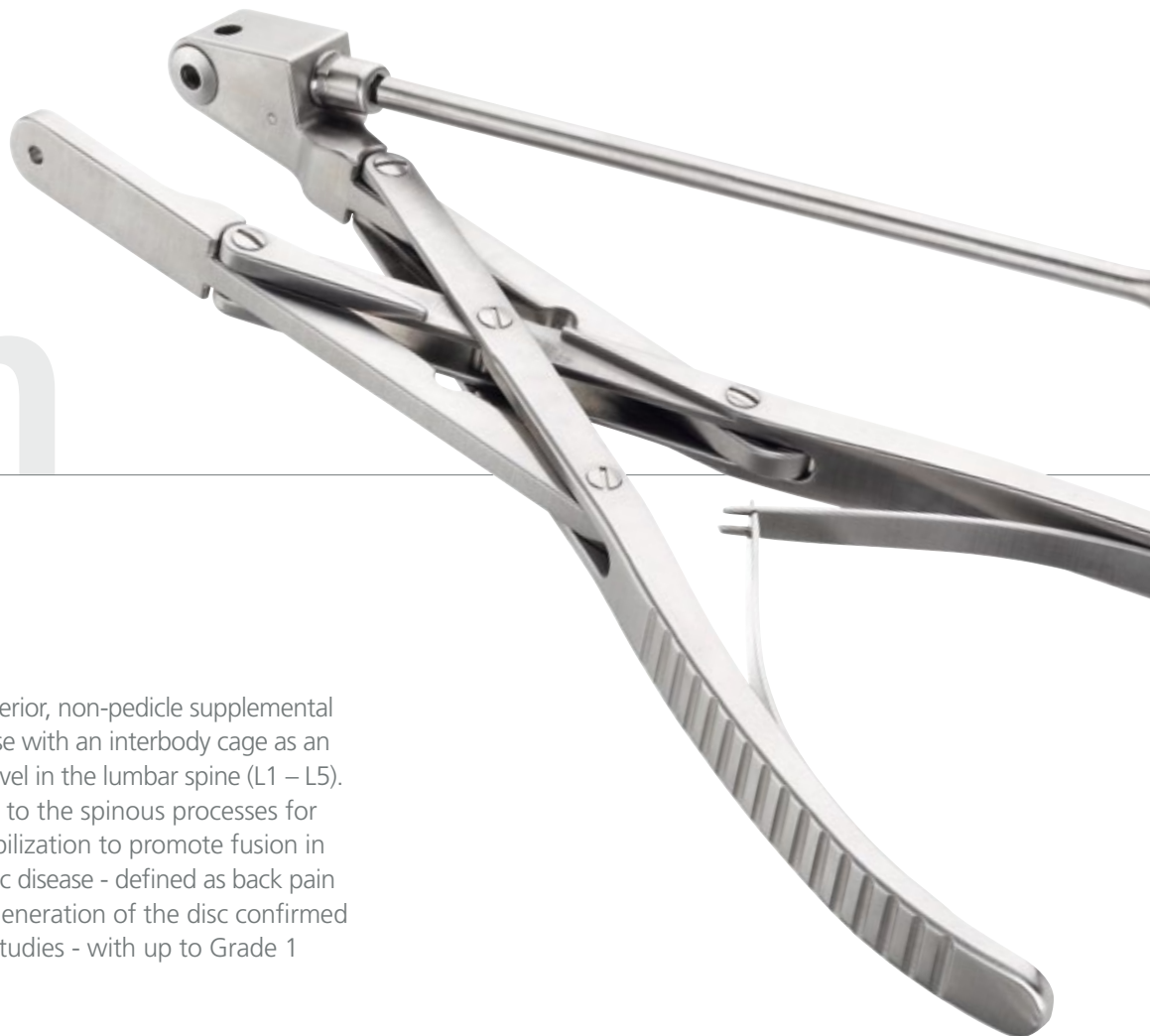

Table 1: Range of motion (ROM) and neutral zone normalized to the intact state (100%). In combination with cages anteriorly both the *coflex-F* implant and the pedicle screw system reduced the ROM significantly.

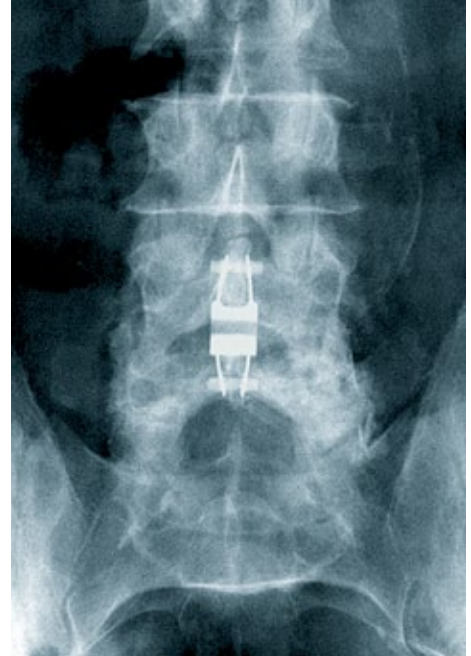
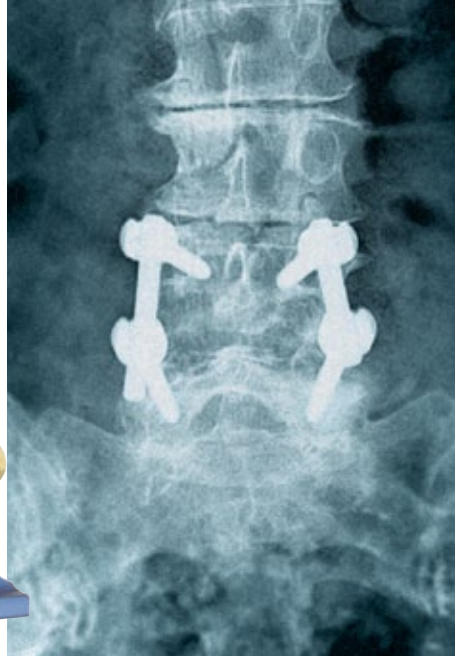


Indication Specific

The *coflex-F* implant is a posterior, non-pedicle supplemental fixation device intended for use with an interbody cage as an adjunct to fusion at a single level in the lumbar spine (L1 – L5). It is intended for attachment to the spinous processes for the purpose of achieving stabilization to promote fusion in patients with degenerative disc disease - defined as back pain of discogenic origin with degeneration of the disc confirmed by history and radiographic studies - with up to Grade 1 spondylolisthesis.



Stabi



The *coflex-F* implant - the minimally invasive alternative to traditional pedicle screw fixation for interbody fusion.

lization

Minimally Invasive

Adjunct to Interbody Fusion

Interlaminar stabilization with the *coflex-F* implant* is an ideal adjunct to fusion in cases of degenerative disc disease with or without mild instabilities in the lumbar spine.

The *coflex-F* implant allows segmental stabilization in combination with interbody fusion cages and is bridging the gap between stand-alone anterior solutions and 360° fusions using pedicle screw fixation.

Design Features:

- Interlaminar positioning
- Secure anchorage through screw and sleeve fixation
- Large contact area for optimized stress distribution
- Five anatomical sizes
- Color coded instrumentation
- Titanium alloy - biocompatible

Reduced Iatrogenic Trauma

- Less muscle trauma
- Less blood loss
- Smaller skin incision

Reduced Surgical Risks

- Excellent safety profile of implant
- Protection of neural structures
- Easy and precise application

Reduced Cost

- Shorter operating time
- Faster patient rehabilitation

Ease of Use

- Simple surgical technique
- Intuitive instrumentation

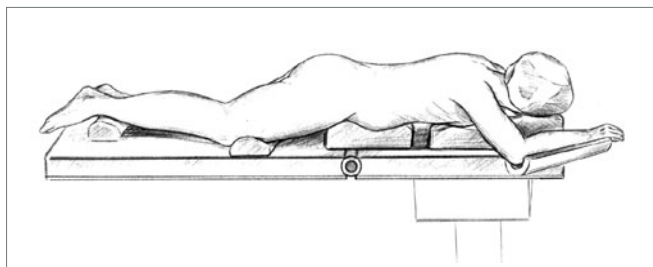
*US Patent 5, 645, 599. Also Patented in other Foreign Countries.
Additional Patents Pending in the U.S. and Worldwide.

Surgical

Technique

1. Lumbar Interbody Fusion

According to the pathology interbody fusion is performed per the surgeon's preference. It is important to note that the *coflex-F* implant is always inserted after implantation of an intervertebral device.



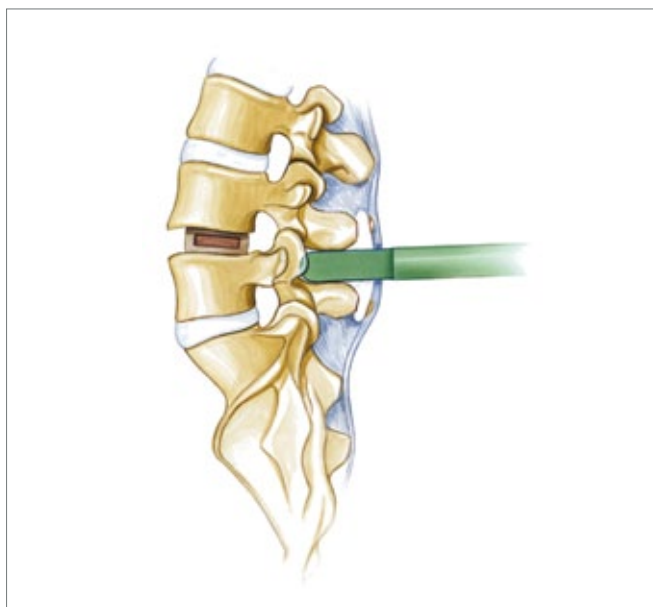
2. Preparation

Once intervertebral fusion has been performed the patient is prepared for posterior stabilization with the *coflex-F* implant. Care should be taken to preserve the facet capsules including at least 50% of the medial facets during cage insertion.

The patient is placed in prone position on a surgical frame avoiding hyperlordosis of the spinal segment(s) to be operated on. Routine (midline) skin incision is performed. The muscle is sharply dissected lateral to the supraspinous ligament. Paraspinal muscles are stripped off the laminae. The interspinous ligament is sacrificed and any bony overgrowth of the spinous process is resected that may interfere with the insertion of the *coflex-F* implant.

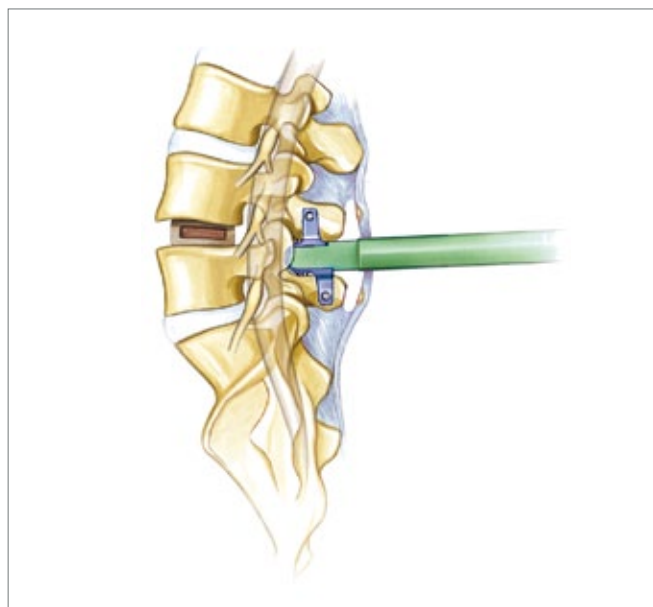
3. Implant Site Preparation

Trials are utilized to define the appropriate implant size. The trial instrument is placed to evaluate proper contact with the spinous processes avoiding any facet distraction. Some bony resection of the spinous process may be needed to ensure optimal contact of the implant.



4. Implant Insertion

The implant is introduced via impaction utilizing a mallet. Prior to insertion the wings may need to be opened slightly using the bending pliers to ensure appropriate depth of insertion (Fig. 1). Proper depth is determined by passing a beaded tip probe between the implant and the dura to ensure a 2-3 mm separation.



By deeply inserting the *coflex-F* implant at the level of the facet joints the implant counteracts the majority of posterior column forces.



Fig. 1

Once proper placement has been achieved, it is recommended to securely crimp the wings of the implant using the crimping pliers (Fig. 2). Then punching pliers are utilized to create a hole in each spinous process for later introduction of the *coflex-F* screws. ▷




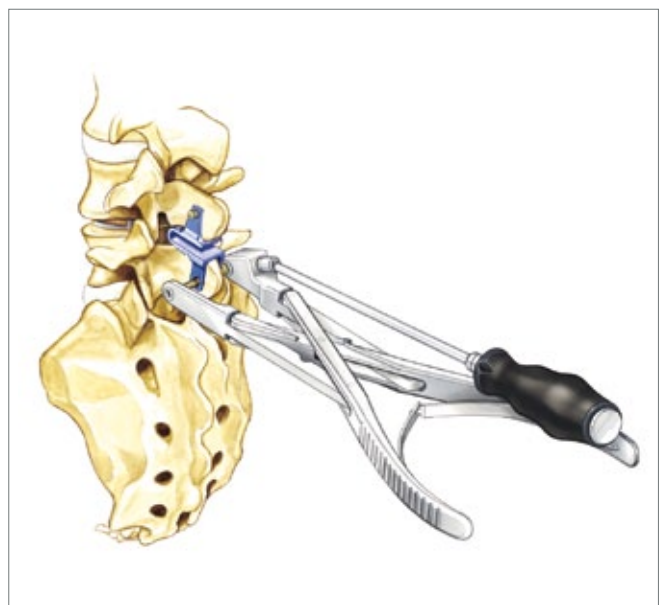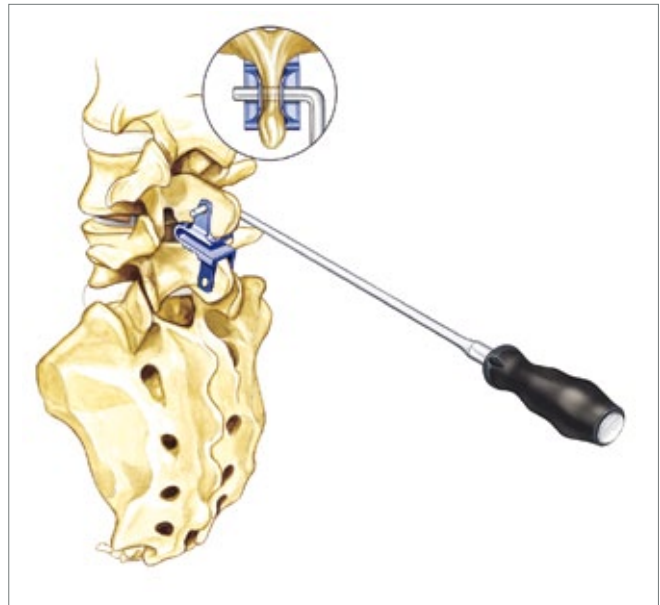
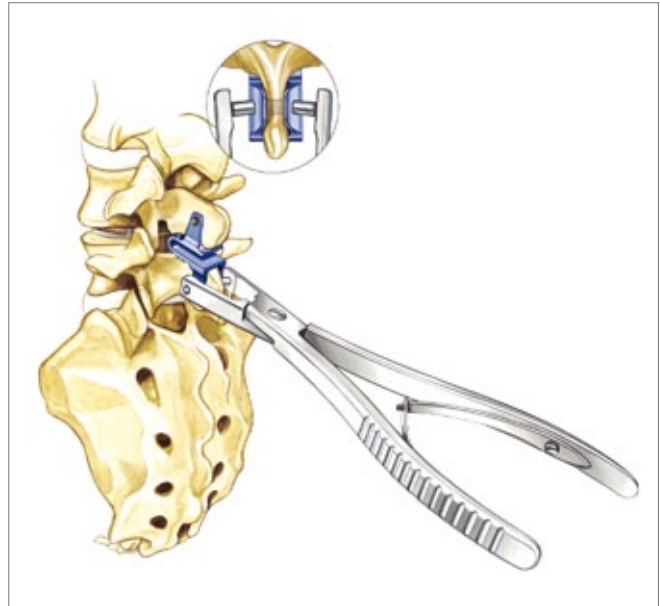
Fig. 2

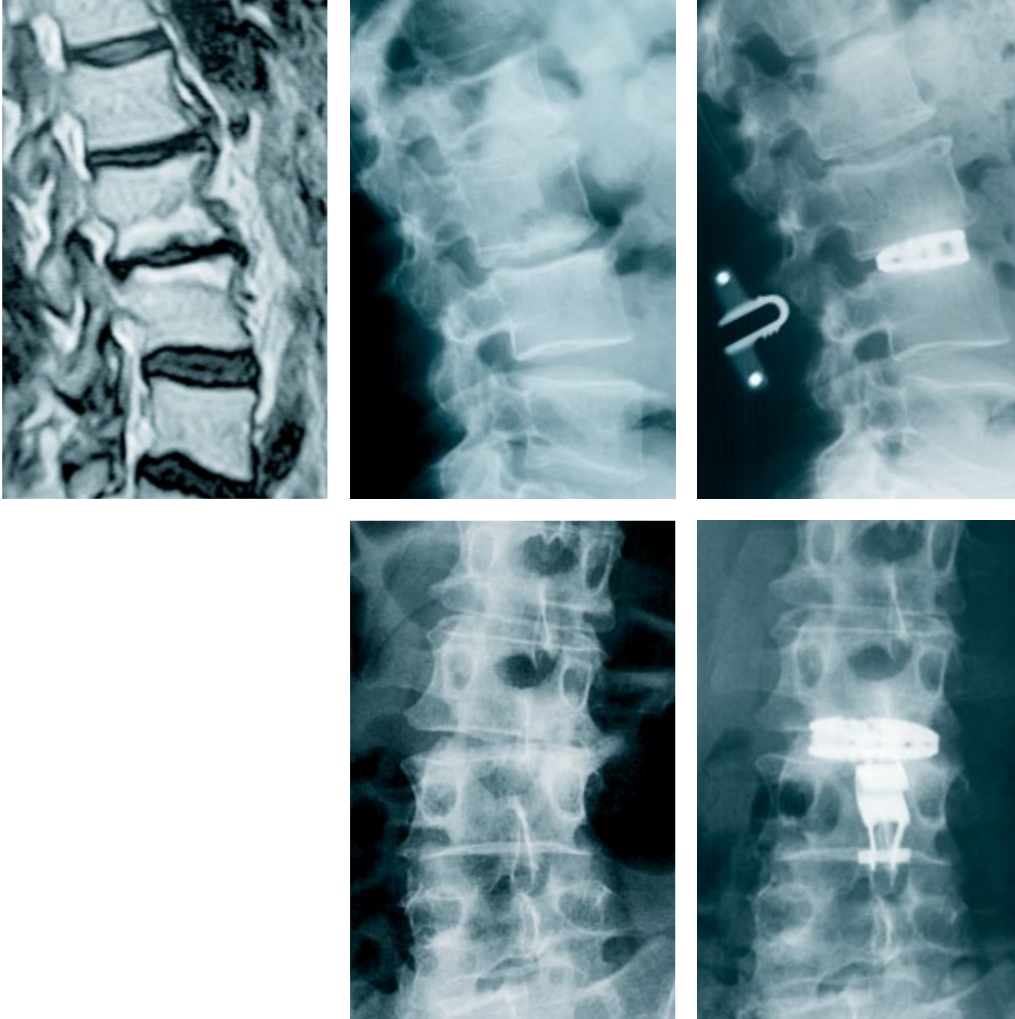Prior to insertion of the *coflex-F* screws it is recommended to clean the holes using the *coflex-F* probe. ▷

The *coflex-F* screws are attached to the screw inserter and applied into the spinous processes using the screw driver. A tight fit is required for controlled fixation. The teeth of both wings should be firmly engaged into the cortices of the spinous processes. ▷

5. Wound Closure

A surgical drain may be placed as per surgeon preference. Paraspinal muscles are reattached to the supraspinous ligament. Skin is closed in the usual manner.





Patient Cas

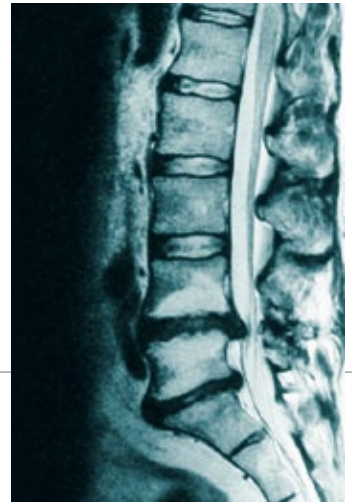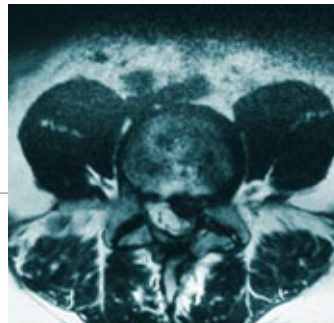
Solution

Case 1: Female, 53 years, Scientific Consultant:

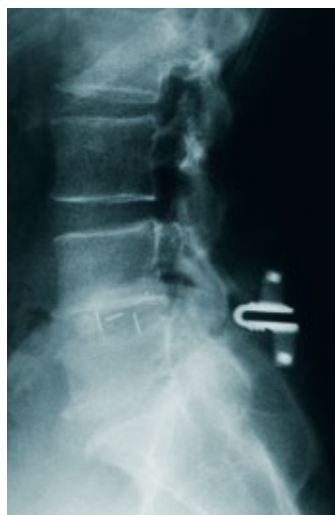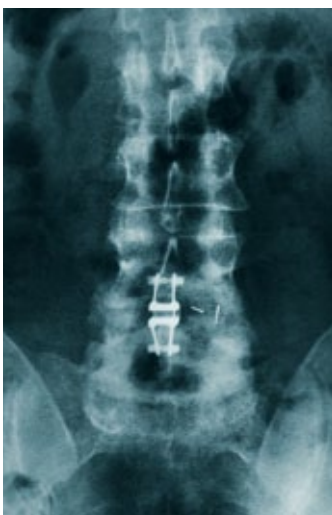- Symptoms: 10+ years of progressive low back pain. 3+ years of sciatic pain and Trendelenburg signs. Reduced walking distance of 50-100 meters.
- MRI: Degenerative disc disease at level L2/3, osteochondrosis at levels L4/5 and L5/S1, disc protrusions at levels L3/4, L4/5 and L5/S1.
- Diagnosis: Degenerative disc disease at level L2/3.
- Previous Therapy: Failed conservative treatment. Infiltrations including discography with improvement for 4 weeks.
- Surgery: Spondylodesis at level L2/3 with ALIF cage (Syncage) and *coflex-F* implant size 10 mm. Bone graft from left iliac crest.
- Follow-up at 12 months: Patient extremely satisfied with treatment. Back pain has improved from VAS 9 preoperatively to 0.7 at 12 months, leg pain improved from VAS 6 to 0. ODI values also show marked improvement from 50 preoperatively to 4 postoperatively at 12 month time point.

Case 2:
Male, 43 years, Papermaker:

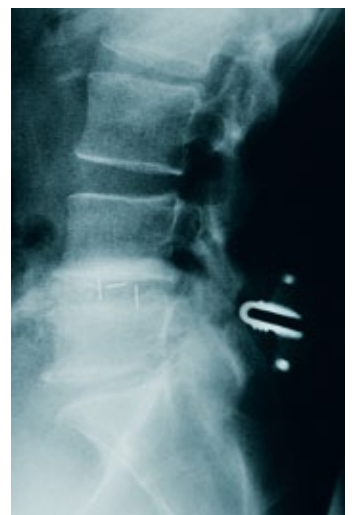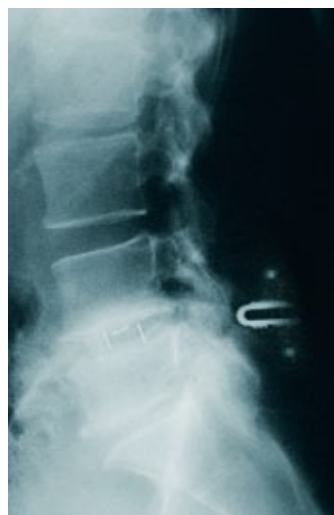- Symptoms: Long history of progressive low back pain. More than 6 months of increasing left leg pain.
- MRI: Degenerative disc disease at level L4/5 and L5/S1. Disc protrusions at levels L4/5 and L5/S1.
- Diagnosis: Degenerative disc disease with mild instability and disc protrusion at level L4/5.
- Previous Therapy: Failed conservative treatment. One microdiscectomy ten years ago and another microdiscectomy three years ago at level L4/5 to the left. Administration of various nerve root blocks.
- Surgery: Microsurgical decompression at level L4/5 and additional implantation of PEEK TLIF cage (Scient'X) and 8mm *coflex-F* implant at level L4/5.
- Follow-up at 12 months: Patient is very satisfied with treatment and stated that he would definitely have the surgery again. ODI and VAS scores showed marked improvement over 12 months timeframe. Bone formation visible at 3 month time point (x-ray AP and lateral), functional x-rays at 8 months show no motion at the L4/5 segment.



3 months postoperative



8 months postoperative



Product





Information

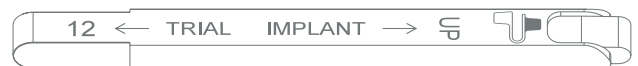Sterilization Tray

RAC 00000

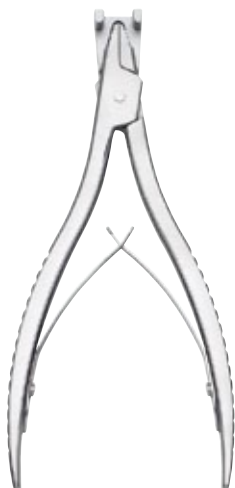

Trials

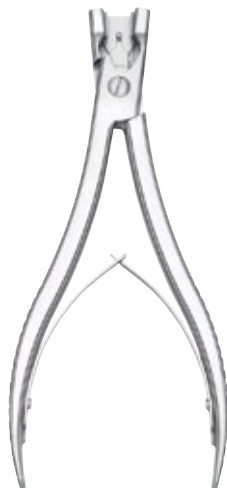
Color Code	Size	Article Number
	16 mm	RCT 00016
	14 mm	RCT 00014
	12 mm	RCT 00012
	10 mm	RCT 00010
	8 mm	RCT 00008



Instruments



Bending Plier
UAT 10100



Crimping Plier
UAT 10200



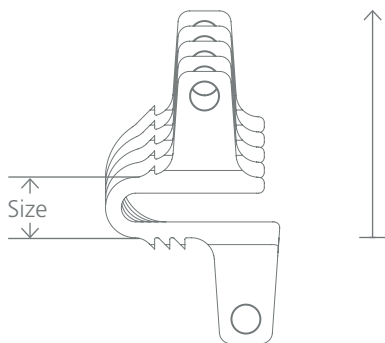
Cleaning Tool
RAT 20130





Punching Plier
RAT 20100



Probe
RAT 20120

coflex-F™ Implant



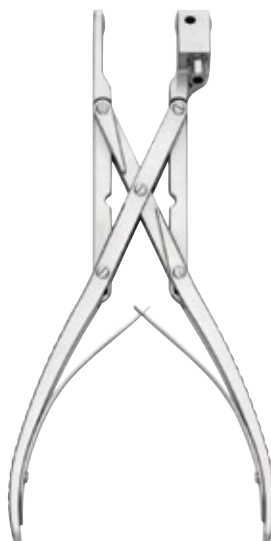Color Code	Size	Article Number
	16 mm	RCI 00016
	14 mm	RCI 00014
	12 mm	RCI 00012
	10 mm	RCI 00010
	8 mm	RCI 00008



Material:
All *coflex-F* implants consist of titanium 6-aluminium 4-vanadium (ISO 5832-3).

MRT:
Titanium is a non ferromagnetic material, therefore magnetic resonance imaging can be done.

◁ The *coflex-F* implant is delivered sterile packed and includes a disposable application tool.



Screw Inserter
RAT 20211



Screwdriver
RAT 20204



Wrench
RAT 20300



PARADIGM SPINE

the movement in spine care

Paradigm Spine GmbH
Eisenbahnstrasse 84
D-78573 Wurmlingen, Germany

Tel +49 (0) 7461 - 96 35 99 - 0
Fax +49 (0) 7461 - 96 35 99 - 20

info@paradigmspine.de
www.paradigmspine.com